A 34-year-old woman is brought to the emergency department by ambulance due to nausea, dizziness, and confusion. Her boyfriend arrives with her and says that he found her lying on the bed next to an empty bottle of aspirin tablets. When asked about the potential ingestion, the patient admits to swallowing a "bunch of aspirin pills a little more than 12 hours ago" after coming home from work. She also describes hearing "an annoying buzzing sound that won't stop." Temperature is 38.3 C (101 F) and pulse is 102/min. She appears agitated and confused. Which of the following sets of laboratory results is most likely to be found in this patient?

	pH	$PaCO_2$	Plasma HCO_3^-
A.	7.26	60 mm Hg	26 mEq/L
B.	7.37	18 mm Hg	10 mEq/L
C.	7.42	40 mm Hg	25 mEq/L
D.	7.47	48 mm Hg	34 mEq/L
E.	7.60	24 mm Hg	23 mEq/L

Submit

A 34-year-old woman is brought to the emergency department by ambulance due to nausea, dizziness, and confusion. Her boyfriend arrives with her and says that he found her lying on the bed next to an empty bottle of aspirin tablets. When asked about the potential ingestion, the patient admits to swallowing a "bunch of aspirin pills a little more than 12 hours ago" after coming home from work. She also describes hearing "an annoying buzzing sound that won't stop." Temperature is 38.3 C (101 F) and pulse is 102/min. She appears agitated and confused. Which of the following sets of laboratory results is most likely to be found in this patient?

	pH	$PaCO_2$	Plasma HCO_3^-
A. (18%)	7.26	60 mm Hg	26 mEq/L
✓ B. (59%)	7.37	18 mm Hg	10 mEq/L
C. (2%)	7.42	40 mm Hg	25 mEq/L
D. (7%)	7.47	48 mm Hg	34 mEq/L
E. (11%)	7.60	24 mm Hg	23 mEq/L

Omitted
Correct answer
B

59%
Answered correctly

07 secs
Time Spent

03/30/2020
Last Updated

Acute salicylate intoxication typically presents with nausea/vomiting, dizziness, confusion, **tinnitus** (eg, ringing/buzzing sound), **fever**, and **tachypnea** within several hours after ingestion. Two different acid-base abnormalities are characteristic:

- **Primary respiratory alkalosis** occurs because salicylates directly stimulate the medullary respiratory center, resulting in increased ventilation and loss of CO_2 in the expired air.
- **Primary anion gap metabolic acidosis** develops because toxic salicylate levels increase lipolysis, uncouple oxidative phosphorylation, and inhibit the citric acid cycle. This results in the accumulation of unmeasured organic acids in the blood (eg, ketoacids, lactate), increasing the anion gap.

Therefore, salicylate toxicity classically presents with a **mixed acid-base disturbance**, with arterial blood gas sometimes showing a **pH within the normal range** as the 2 primary disturbances shift the pH in opposite directions. There is **low serum HCO_3^-** due to primary metabolic acidosis and **low $PaCO_2$** due to both respiratory compensation for the metabolic acidosis and the primary respiratory alkalosis. Because of the mixed disturbance, the **$PaCO_2$ is lower than expected** for respiratory compensation alone (ie, per Winters' formula the expected $PaCO_2$ due to respiratory compensation is ~23 mm Hg, but the primary increase in central respiratory drive pushes $PaCO_2$ even lower).

(Choice A) Low pH with elevated $PaCO_2$ is consistent with primary respiratory acidosis, which can occur with the respiratory depression seen with opioid overdose. HCO_3^- is slightly elevated, which is consistent with the small degree of metabolic compensation that occurs in the acute setting; full metabolic compensation requires approximately 72 hours.

(Choice C) These values are consistent with normal acid-base status.

(Choice D) High pH with elevated HCO_3^- represents primary metabolic alkalosis, which can occur with intractable vomiting. $PaCO_2$ is elevated and consistent with appropriate respiratory compensation.

(Choice E) High pH with low $PaCO_2$ and near normal HCO_3^- represent primary respiratory alkalosis with minimal metabolic compensation. This can occur with any cause of acute hyperventilation (eg, panic attack).

Educational objective:
Salicylate intoxication should be suspected in patients with the triad of fever, tinnitus, and tachypnea. Salicylates both stimulate central respiratory drive to cause primary respiratory alkalosis and disrupt cellular metabolism to cause primary anion gap metabolic acidosis. Therefore, toxicity classically presents with a mixed acid-base disturbance and a blood pH sometimes within the normal range.

Therefore, salicylate toxicity classically presents with a **mixed acid-base disturbance**, with arterial blood gas sometimes showing a **pH within the normal range** as the 2 primary disturbances shift the pH in opposite directions. There is **low serum HCO_3^-** due to primary metabolic acidosis and **low $PaCO_2$** due to both respiratory compensation for the metabolic acidosis and the primary respiratory alkalosis. Because of the mixed disturbance, the **$PaCO_2$ is lower than expected** for respiratory compensation alone (ie, per Winters' formula the expected $PaCO_2$ due to respiratory compensation is ~23 mm Hg, but the primary increase in central respiratory drive pushes $PaCO_2$ even lower).

(Choice A) Low pH with elevated $PaCO_2$ is consistent with primary respiratory acidosis, which can occur with the respiratory depression seen with opioid overdose. HCO_3^- is slightly elevated, which is consistent with the small degree of metabolic compensation that occurs in the acute setting; full metabolic compensation requires approximately 72 hours.

(Choice C) These values are consistent with normal acid-base status.

(Choice D) High pH with elevated HCO_3^- represents primary metabolic alkalosis, which can occur with intractable vomiting. $PaCO_2$ is elevated and consistent with appropriate respiratory compensation.

(Choice E) High pH with low $PaCO_2$ and near normal HCO_3^- represent primary respiratory alkalosis with minimal metabolic compensation. This can occur with any cause of acute hyperventilation (eg, panic attack).

Educational objective:

Salicylate intoxication should be suspected in patients with the triad of fever, tinnitus, and tachypnea. Salicylates both stimulate central respiratory drive to cause primary respiratory alkalosis and disrupt cellular metabolism to cause primary anion gap metabolic acidosis. Therefore, toxicity classically presents with a mixed acid-base disturbance and a blood pH sometimes within the normal range.

References

- Salicylate intoxication: a clinical review.

Pathophysiology	Poisoning & Environmental Exposure	Salicylate poisoning
Subject	System	Topic

Copyright © UWorld. All rights reserved.

Acute salicylate intoxication typically presents with nausea/vomiting, dizziness, confusion, **tinnitus** (eg, ringing/buzzing sound), **fever**, and

Exhibit Display



Zoom In | Zoom Out | Reset | Add To New Card | Existing Card

drive to cause primary respiratory alkalosis and disrupt cellular metabolism to cause primary anion gap metabolic acidosis. Therefore, toxicity

Acute salicylate intoxication typically presents with nausea/vomiting, dizziness, confusion, **tinnitus** (eg, ringing/buzzing sound), **fever**, and **tachypnea** within several

- **Primary respirator**
  ventilation and loss
- **Primary anion gap**
  and inhibit the citric
  increasing the anion

Therefore, salicylate toxici
the normal range as the
and **low PaCO2** due to bo
disturbance, the **$PaCO_2$ is**
respiratory compensation

(Choice A) Low pH with
with opioid overdose. HC
setting; full metabolic com

(Choice C) These values

(Choice D) High pH with
and consistent with appro

(Choice E) High pH with
can occur with any cause

Educational objective:
Salicylate intoxication sho
drive to cause primary respiratory alkalosis and disrupt cellular metabolism to cause primary anion gap metabolic acidosis. Therefore, toxicity

osis

d

is

tory

Exhibit Display

Appropriate compensatory $PaCO_2$ or bicarbonate changes in acid-base disorders

Metabolic acidosis (acute or chronic)	Expected $PaCO_2$ = (1.5 × bicarbonate) + 8 ± 2 (Winters formula)
Metabolic alkalosis (acute or chronic)	~7 mm Hg ↑ in $PaCO_2$ per 10 mEq/L ↑ in bicarbonate
Respiratory acidosis (chronic only*)	~4 mEq/L ↑ in bicarbonate per 10 mm Hg ↑ in $PaCO_2$
Respiratory alkalosis (chronic only*)	~4 mEq/L ↓ in bicarbonate per 10 mm Hg ↓ in $PaCO_2$

*Compensation for respiratory disturbances is minimal in the acute setting. The full level of chronic compensation is achieved after ~72 hr. For simplicity, normal baseline $PaCO_2$ and bicarbonate should be considered 40 mm Hg and 24 mEq/L, respectively.

Add To New Card | Existing Card

Settings

1
2
3
4
5

Item 2 of 5
Question Id: 19108

Mark | Previous | Next | Full Screen | Tutorial | Lab Values | Notes | Calculator | Reverse Color | Text Zoom | Settings

A 67-year-old man is brought to the hospital after he developed sudden-onset altered mental status. The patient was taking care of some yardwork alongside his 17-year-old grandson during a hot summer day. The grandson does not have any symptoms. On examination, the patient's temperature is 41 C (105.8 F), blood pressure is 90/60 mm Hg, pulse is 120/min, and respirations are 24/min. Examination shows warm and dry skin. The patient is not oriented to time, place, or person. Deep tendon reflexes and muscle tone are normal. Which of the following findings in this patient most likely explains why the patient developed symptoms while his grandson remained asymptomatic?

A. Decreased effective epidermal area available for heat transfer

B. Decreased vasodilation of the splanchnic vasculature

C. Increased heat transfer to the skin due to reduced subcutaneous fat

D. Increased number of sweat glands

E. Increased peripheral vasodilation of the skin

Submit

Block Time Remaining: 00:00:08
TUTOR

0 | Feedback | Suspend | End Block

A 67-year-old man is brought to the hospital after he developed sudden-onset altered mental status. The patient was taking care of some yardwork alongside his 17-year-old grandson during a hot summer day. The grandson does not have any symptoms. On examination, the patient's temperature is 41 C (105.8 F), blood pressure is 90/60 mm Hg, pulse is 120/min, and respirations are 24/min. Examination shows warm and dry skin. The patient is not oriented to time, place, or person. Deep tendon reflexes and muscle tone are normal. Which of the following findings in this patient most likely explains why the patient developed symptoms while his grandson remained asymptomatic?

- ✓ A. Decreased effective epidermal area available for heat transfer (42%)
- B. Decreased vasodilation of the splanchnic vasculature (20%)
- C. Increased heat transfer to the skin due to reduced subcutaneous fat (21%)
- D. Increased number of sweat glands (1%)
- E. Increased peripheral vasodilation of the skin (13%)

Omitted
Correct answer
A

42%
Answered correctly

02 secs
Time Spent

06/25/2020
Last Updated

Explanation

Causes of heat intolerance	
	• Deconditioning/poor physical fitness • Lack of acclimation to elevated ambient temperatures

Causes of heat intolerance	
Functional	• Deconditioning/poor physical fitness • Lack of acclimation to elevated ambient temperatures • Reduced skin surface-to-body mass ratio (eg, obesity, high muscle volume, elderly patients) • Aging-related tonic vasoconstriction of peripheral vasculature • Inherited sweat gland dysfunction
Acquired	• Drugs/medications (eg, stimulants, anticholinergics, diuretics, alcohol) • Dehydration • Large areas of scarring (eg, due to burns)

This elderly patient developed hyperthermia and altered mental status while working outside on a hot summer day. This presentation suggests exertional **heat stroke**, a life-threatening multisystem disorder characterized by **hyperthermia** (typically >40 C [104 F]) associated with **central nervous system dysfunction** (eg, encephalopathy, as seen in this disoriented patient). Other classic manifestations of heat stroke include tachycardia, tachypnea, hypotension, flushing, and end-organ dysfunction (eg, pulmonary edema, renal or hepatic failure). Diaphoresis may or may not be present on examination, depending on hydration status.

Normal thermoregulatory response to elevated temperatures include increased sweating and increased cardiac output. Furthermore, there is significant peripheral vasodilation and splanchnic vasoconstriction, which shunts blood to the periphery to aid with heat transfer. However, **elderly** patients are at particularly high risk of developing heat-related illness due to several features of normal aging that impair this response, including:

- Tonic contraction of the peripheral vasculature, which limits heat transfer to the skin
- **Reduced sweat gland density**, which limits the ability to dissipate heat via evaporation
- Loss of rete pegs and dermal capillaries, which **reduces the effective epidermal area available for heat transfer**

In addition, many elderly patients have medical conditions (eg, congestive heart failure) or are taking medications that may limit cardiac output (eg, beta blockers), diaphoresis (eg, anticholinergics), or blood volume available for heat transfer (eg, diuretics).

may not be present on examination, depending on hydration status.

Normal thermoregulatory response to elevated temperatures include increased sweating and increased cardiac output. Furthermore, there is significant peripheral vasodilation and splanchnic vasoconstriction, which shunts blood to the periphery to aid with heat transfer. However, **elderly** patients are at particularly high risk of developing heat-related illness due to several features of normal aging that impair this response, including:

- Tonic contraction of the peripheral vasculature, which limits heat transfer to the skin
- **Reduced sweat gland density**, which limits the ability to dissipate heat via evaporation
- Loss of rete pegs and dermal capillaries, which **reduces the effective epidermal area available for heat transfer**

In addition, many elderly patients have medical conditions (eg, congestive heart failure) or are taking medications that may limit cardiac output (eg, beta blockers), diaphoresis (eg, anticholinergics), or blood volume available for heat transfer (eg, diuretics).

(Choices B and E) Appropriate responses to elevated temperature include decreased vasodilation (ie, vasoconstriction) of the splanchnic vasculature, which promotes blood flow from the internal organs to the skin, and peripheral vasodilation, which allows for heat dissipation.

(Choice C) Loss of subcutaneous fat also often occurs with aging and reduces the ability to retain heat and allows increased heat transfer to the skin; however, this promotes cooling (and places elderly patients at increased risk for hypothermia).

(Choice D) An increased number of sweat glands would promote cooling in patients with hyperthermia; however, sweat glands are typically reduced with aging, not increased.

Educational objective:
Elderly patients are at increased risk of developing heat-related illness due to several features of normal aging that impair normal thermoregulatory mechanisms, including tonic contraction of the peripheral vasculature, reduced sweat gland density, and reduced effective epidermal area available for heat transfer.

Pathophysiology	Poisoning & Environmental Exposure	Heat related illness
Subject	System	Topic

Copyright © UWorld. All rights reserved.

Settings

1
2
3
4
5

Item 3 of 5
Question Id: 15762

Mark | Previous | Next | Full Screen | Tutorial | Lab Values | Notes | Calculator | Reverse Color | Text Zoom | Settings

A 12-year-old girl is brought to the office by her mother due to unusual nighttime behavior. The mother reports that once or twice a month over the past year she has found her daughter walking around the house between the hours of midnight and 2 AM. The mother says, "Although her eyes are open, she appears to be in a daze and doesn't respond to me. I guide her back to bed and she goes back to sleep, but I worry that she could get hurt or fall down the stairs if I'm not there." The girl has no recollection of the events. Which of the following EEG patterns is characteristic of the sleep stage associated with this behavior?

A. Alpha waves
B. Beta waves
C. Delta waves
D. K complexes
E. Sleep spindles

Submit

Block Time Remaining: 00:00:10
TUTOR

2 | Feedback | Suspend | End Block

A 12-year-old girl is brought to the office by her mother due to unusual nighttime behavior. The mother reports that once or twice a month over the past year she has found her daughter walking around the house between the hours of midnight and 2 AM. The mother says, "Although her eyes are open, she appears to be in a daze and doesn't respond to me. I guide her back to bed and she goes back to sleep, but I worry that she could get hurt or fall down the stairs if I'm not there." The girl has no recollection of the events. Which of the following EEG patterns is characteristic of the sleep stage associated with this behavior?

A. Alpha waves (4%)
B. Beta waves (8%)
✓ C. Delta waves (74%)
D. K complexes (7%)
E. Sleep spindles (6%)

Omitted
Correct answer
C

74%
Answered correctly

03 secs
Time Spent

02/19/2020
Last Updated

Explanation

Sleep stages		
	EEG pattern & frequencies	Characteristics/pathology
		• Wakefulness-sleep transition

Sleep stages		
	EEG pattern & frequencies	**Characteristics/pathology**
Non-REM stage 1 (N1)	• Theta waves (4-7.9 Hz)	• Wakefulness-sleep transition • Easy to wake
Non-REM stage 2 (N2)	• Theta waves (4-7.9 Hz) • Sleep spindles & K-complexes	• Largest percentage of sleep
Non-REM stage 3 (N3)	• Delta waves (<4 Hz)	• Prominent 1st half of night • Difficult to wake • Sleepwalking & night terrors
REM	• EEG resembles wakefulness • Occasional sawtooth waves	• Prominent 2nd half of night • Dreams, rapid eye movements, muscle atonia • REM sleep behavior disorder & nightmare disorder

This girl's nighttime ambulation associated with incomplete arousal and amnesia for the event is consistent with **sleepwalking**, a non-REM (NREM) parasomnia. Sleepwalking is more common in children, peaks at age 8-12, and often remits spontaneously. **NREM-related parasomnias** such as sleepwalking and sleep terrors occur during **deep, slow-wave sleep**. Deep, slow-wave sleep is more prominent during the first half of the night and, as a result, NREM-related parasomnias occur more commonly during this time.

Sleep is divided into NREM and REM sleep. Most dreams occur during REM sleep. NREM sleep is further divided into 3 substages based on depth of sleep (N1, N2, and N3). Brain waves of different frequencies are associated with different stages of sleep. **Delta waves** (frequency up to 3.99 Hz) are characteristic of deep, slow-wave sleep (stage N3). Alpha and beta waves are characteristic of wakefulness and REM sleep **(Choices A and B)**. K complexes and Sleep spindles are characteristic of stage N2 (light, stable sleep) **(Choices D and E)**.

Educational objective:
Sleepwalking, a common non-REM parasomnia of childhood, occurs during slow-wave sleep (stage N3), which is characterized by delta waves on EEG. Sleepwalking typically occurs during the first half of the night, when slow-wave sleep is most prominent.

REM	• EEG resembles wakefulness • Occasional sawtooth waves	• Prominent 2nd half of night • Dreams, rapid eye movements, muscle atonia • REM sleep behavior disorder & nightmare disorder

This girl's nighttime ambulation associated with incomplete arousal and amnesia for the event is consistent with **sleepwalking**, a non-REM (NREM) parasomnia. Sleepwalking is more common in children, peaks at age 8-12, and often remits spontaneously. **NREM-related parasomnias** such as sleepwalking and sleep terrors occur during **deep, slow-wave sleep**. Deep, slow-wave sleep is more prominent during the first half of the night and, as a result, NREM-related parasomnias occur more commonly during this time.

Sleep is divided into NREM and REM sleep. Most dreams occur during REM sleep. NREM sleep is further divided into 3 substages based on depth of sleep (N1, N2, and N3). Brain waves of different frequencies are associated with different stages of sleep. **Delta waves** (frequency up to 3.99 Hz) are characteristic of deep, slow-wave sleep (stage N3). Alpha and beta waves are characteristic of wakefulness and REM sleep **(Choices A and B)**. K complexes and Sleep spindles are characteristic of stage N2 (light, stable sleep) **(Choices D and E)**.

Educational objective:
Sleepwalking, a common non-REM parasomnia of childhood, occurs during slow-wave sleep (stage N3), which is characterized by delta waves on EEG. Sleepwalking typically occurs during the first half of the night, when slow-wave sleep is most prominent.

References

- Electroencephalographic slow waves prior to sleepwalking episodes.
- Non-rapid eye movement arousal parasomnias in children.
- Prevalence of sleepwalking: a systematic review and meta-analysis.

Pathophysiology	Psychiatric/Behavioral & Substance Abuse	Parasomnias
Subject	System	Topic

Copyright © UWorld. All rights reserved.

Settings

1
2
3
4
5

Item 4 of 5
Question Id: 15609

Mark | Previous | Next | Full Screen | Tutorial | Lab Values | Notes | Calculator | Reverse Color | Text Zoom | Settings

A 6-year-old boy is brought to the office by his mother due to behavioral difficulties at school. His teacher has said, "He interrupts the class, doesn't listen, and cannot sit still for more than a few minutes." He has been sent home on a few occasions for hitting other children and taking their toys. The patient was adopted at age 6 months and his birth history is unknown. He runs around the office playing with various toys and is easily distracted. Vital signs are within normal limits. Weight and height are tracking on the 10th percentile, and head circumference is below the 5th percentile for age and sex. Physical examination reveals short palpebral fissures, a smooth philtrum, thin upper lip, and difficulty with both gross and fine motor coordination. Which of the following is the likely cause of this patient's condition?

- A. CGG trinucleotide repeat
- B. Intrauterine alcohol exposure
- C. Intrauterine cocaine exposure
- D. Intrauterine rubella exposure
- E. Trisomy 18
- F. Trisomy 21

Submit

Block Time Remaining: 00:00:12
TUTOR

3 | Feedback | Suspend | End Block

A 6-year-old boy is brought to the office by his mother due to behavioral difficulties at school. His teacher has said, "He interrupts the class, doesn't listen, and cannot sit still for more than a few minutes." He has been sent home on a few occasions for hitting other children and taking their toys. The patient was adopted at age 6 months and his birth history is unknown. He runs around the office playing with various toys and is easily distracted. Vital signs are within normal limits. Weight and height are tracking on the 10th percentile, and head circumference is below the 5th percentile for age and sex. Physical examination reveals short palpebral fissures, a smooth philtrum, thin upper lip, and difficulty with both gross and fine motor coordination. Which of the following is the likely cause of this patient's condition?

- A. CGG trinucleotide repeat (1%)
- ✓ B. Intrauterine alcohol exposure (87%)
- C. Intrauterine cocaine exposure (1%)
- D. Intrauterine rubella exposure (0%)
- E. Trisomy 18 (1%)
- F. Trisomy 21 (7%)

Omitted
Correct answer
B

87%
Answered correctly

02 secs
Time Spent

02/16/2020
Last Updated

Explanation

Fetal alcohol syndrome

Settings

1
2
3
4
5

Item 4 of 5
Question Id: 15609

Mark | Previous | Next | Full Screen | Tutorial | Lab Values | Notes | Calculator | Reverse Color | Text Zoom | Settings

Fetal alcohol syndrome

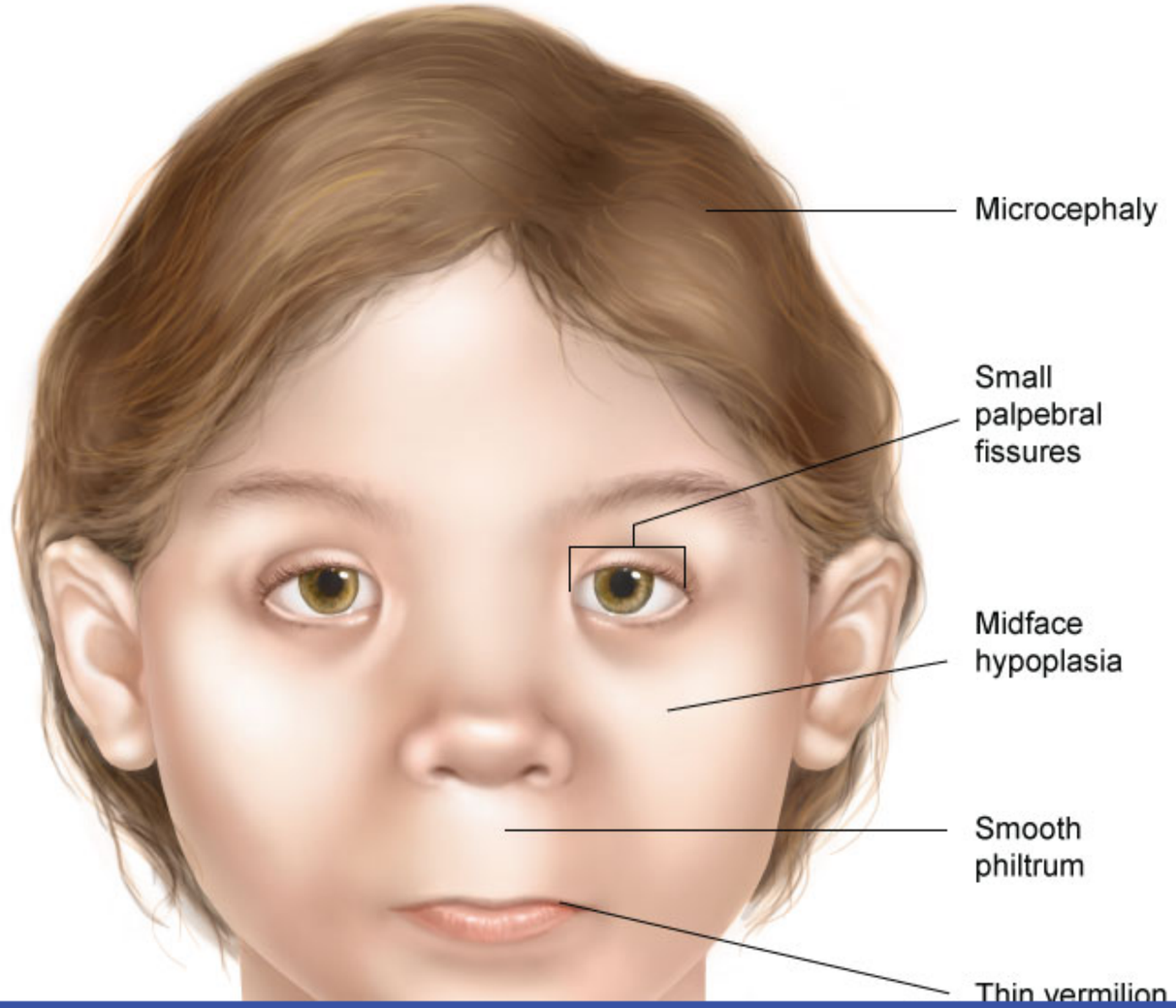

Block Time Remaining: 00:00:14
TUTOR

3 | Feedback | Suspend | End Block

©UWorld

This child's behavioral difficulties (distractibility, hyperactivity, hitting), growth retardation, poor coordination, and facial anomalies are suggestive of **fetal alcohol syndrome (FAS)**. Alcohol is a teratogen that affects multiple organ systems (eg, heart, joints, kidneys, visual systems, auditory systems), most characteristically the CNS. Features of FAS include **facial dysmorphism** (short palpebral fissures, thin upper lip, smooth philtrum), **growth retardation**, and **CNS involvement** (structural and/or neurobehavioral).

Intrauterine alcohol exposure can cause reduction in the volume of the caudate, striatum, thalamus, and cerebellum, resulting in abnormal reflexes, tone, and coordination. A decrease in the volume of the frontal lobe and dysfunction of the amygdala contribute to deficits in executive functioning, impulse control, and emotion regulation. Other **neurobehavioral manifestations** include cognitive impairment, learning disabilities, and social skill deficits.

(Choice A) Fragile X syndrome is caused by unstable CGG (cytosine-guanine-guanine) trinucleotide repeats on the X chromosome. Features include intellectual disability; a long, narrow face; large, protruding ears; macrocephaly; and macroorchidism.

(Choice C) Cocaine exposure in utero is associated with hypertonia and tremors in neonates and impairments in attention, language development, and behavioral regulation in school-aged children. It would not cause the facial anomalies seen in this patient.

(Choice D) Rubella exposure in utero is associated with congenital heart defects, hearing impairment, and ocular abnormalities (eg, glaucoma, cataracts, retinopathy).

(Choice E) Trisomy 18 (Edwards syndrome) is associated with a small mouth and prominent forehead; pointy ears; and flexed, overlapping fingers. Horseshoe kidney and congenital heart defects may be present. Survival beyond one year of age is uncommon and associated with severe intellectual disability.

(Choice F) Facial features in trisomy 21 (Down syndrome) include epicanthal folds, upslanting palpebral fissures, brachycephaly (back of the head symmetrically flattened), flat nasal bridge, and protruding tongue. It is associated with varying degrees of intellectual disability.

Educational objective:
Typical features of fetal alcohol syndrome include facial dysmorphism (short palpebral fissures, thin upper lip, smooth philtrum), growth retardation, neurological abnormalities, and behavioral difficulties.

Settings

1
2
3
4
5

Item 5 of 5
Question Id: 15523

Mark | Previous | Next | Full Screen | Tutorial | Lab Values | Notes | Calculator | Reverse Color | Text Zoom | Settings

A 6-year-old boy is brought to the office due to frequent nighttime awakenings. Several times a week over the past month, he has come to his parents' bed around 3 AM, frequently crying, appearing frightened, and saying that he became lost in a crowd and couldn't find his parents. Although he is comforted by their reassurance, he refuses to return to his room and eventually falls back asleep in their bed. The boy is about to start first grade at a new school. He is healthy and developmental milestones are normal. Examination shows no abnormalities. The sleep stage associated with this child's frightening experience is characterized by which of the following?

A. Increased duration in first third of the night

B. Low-amplitude theta EEG waves

C. Muscle paralysis

D. Sleep spindles and K complexes on EEG

E. Slow-wave sleep (delta EEG waves)

Submit

Block Time Remaining: 00:00:15
TUTOR

2 | Feedback | Suspend | End Block

A 6-year-old boy is brought to the office due to frequent nighttime awakenings. Several times a week over the past month, he has come to his parents' bed around 3 AM, frequently crying, appearing frightened, and saying that he became lost in a crowd and couldn't find his parents. Although he is comforted by their reassurance, he refuses to return to his room and eventually falls back asleep in their bed. The boy is about to start first grade at a new school. He is healthy and developmental milestones are normal. Examination shows no abnormalities. The sleep stage associated with this child's frightening experience is characterized by which of the following?

- A. Increased duration in first third of the night (5%)
- B. Low-amplitude theta EEG waves (5%)
- ✓ C. Muscle paralysis (46%)
- D. Sleep spindles and K complexes on EEG (17%)
- E. Slow-wave sleep (delta EEG waves) (25%)

Omitted
Correct answer
C

46%
Answered correctly

03 secs
Time Spent

02/09/2020
Last Updated

Explanation

This boy's recurrent awakenings with associated dream content and ability to be comforted are characteristic of **nightmares**, a common and developmentally normal experience for most children. Nightmares occur during **rapid eye movement (REM) sleep** and are more frequent in the **final third of the night** when REM periods become longer **(Choice A)**. Children can often describe the nightmare, become fully alert after awakening, and are typically able to be consoled. In contrast, sleep terrors are a common non-REM parasomnia of childhood that occur during slow-wave sleep in the first third of the night. Unlike nightmares, the child with sleep terrors does not fully awaken, is unresponsive to comfort, and

This boy's recurrent awakenings with associated dream content and ability to be comforted are characteristic of **nightmares**, a common and developmentally normal experience for most children. Nightmares occur during **rapid eye movement (REM) sleep** and are more frequent in the **final third of the night** when REM periods become longer **(Choice A)**. Children can often describe the nightmare, become fully alert after awakening, and are typically able to be consoled. In contrast, sleep terrors are a common non-REM parasomnia of childhood that occur during slow-wave sleep in the first third of the night. Unlike nightmares, the child with sleep terrors does not fully awaken, is unresponsive to comfort, and has no associated dream content.

REM sleep is characterized by the defining feature of **rapid eye movements**, **vivid dreaming**, and **voluntary muscle atonia** due to inhibition of motor neurons. EEG activity during REM sleep is similar to the waking state, consisting of a combination of alpha, beta, and desynchronous EEG waves (sawtooth waves).

(Choices B, D, and E) These EEG findings are characteristic of different sub stages of non-REM sleep (typically divided into 3 stages). Theta waves are seen in stage 1 (transition from wakefulness to sleep) and stage 2 (light, stable sleep). Sleep spindles and K complexes are characteristic of stage 2. Delta waves are characteristic of slow-wave sleep or deep sleep (stage 3). Non-REM arousal disorders (eg, sleep terrors) often occur in stage 3.

Educational objective:
REM sleep is characterized by dreaming and voluntary muscle paralysis, and occurs more often during the final third of the night. Nightmares occur during REM sleep and can be differentiated from sleep terrors, a non-REM parasomnia characterized by incomplete arousals and lack of recall of dream content.

References

- REM sleep at its core – circuits, neurotransmitters, and pathophysiology.
- Just a scary dream? A brief review of sleep terrors, nightmares, and rapid eye movement sleep behavior disorder.

Pathophysiology	Psychiatric/Behavioral & Substance Abuse	Parasomnias
Subject	System	Topic

Copyright © UWorld. All rights reserved.